

THE IMPACT OF A MONOFILAMENT DEBRIDEMENT PAD* IN THE MANAGEMENT OF ACTINIC KERATOSIS

Anita Heron – Clinical Sister – Dermatology and Tissue Viability and Georgina Maginn – Staff Nurse, Southern Trust, Northern Ireland.

About Actinic keratosis (AK) (also known as solar keratosis)

Symptoms:

- dry, scaly patches of skin
- most commonly on the head
- can be itchy and unsightly
- the skin over the lesions can become thick and horn like

Cause: years of sun exposure

Who is most commonly affected?:

- people over the age of 40
- fair-skinned people
- men more than women

Prevalence: affects 19 – 24% of people over 60 years of age †

Treatment:

- minor intervention for the less severe
- photodynamic therapy/cryotherapy/curettage (requiring an anaesthetic) for more severe cases

Outlook: treated lesions will usually go away, but are likely to re-develop

Bob (not his real name), aged 73 years presented with a history of AK on his scalp which was extremely sensitive and at risk, due to a history of a squamous cell carcinoma excised from the area and then grafted in 2010.

In December 2013 Bob's Practice Nurse identified scale developing in large amounts, causing concern, and resulting in an immediate hospital dermatology referral and appointment.

Following a holistic assessment in hospital and review by a Consultant Dermatologist, a treatment regime of saline and gauze was commenced to remove the scale build up, followed by steroid and emollient therapy. The treatment aim was removal of the significant build-up of slough, chronic pustular dermatosis and thick scale covering 80% of the scalp. This regime continued from December 2013 three times a week for 20 minute appointments over four months, which was not only ineffective, but also caused Bob significant pain and discomfort. There was also a putrid odour which caused considerable distress. Clinicians felt that topical applications were having little effect, as they were unable to penetrate the scaly skin - resulting in the area sloughing over and re-scaling, leading to further clinic visits, which were becoming troublesome for Bob.

In April 2014, as the situation had become unbearable, Bob was reviewed by his Dermatology Nurse Specialist and the decision was made to evaluate a monofilament debridement pad*. The monofilament pad was dampened with warm tap water and used in a firm, but gentle, circular motion across the whole area of the scalp. Within one application, over a period of 4 minutes, 90% of the slough and debris was removed (supported by photographic evidence). During the treatment Bob experienced no pain or discomfort and was delighted with the instant, visible results gained and commented that his scalp felt smoother. One application allowed improved penetration of steroid ointments and emollients, which went on to treat the scalp and the inflammation.

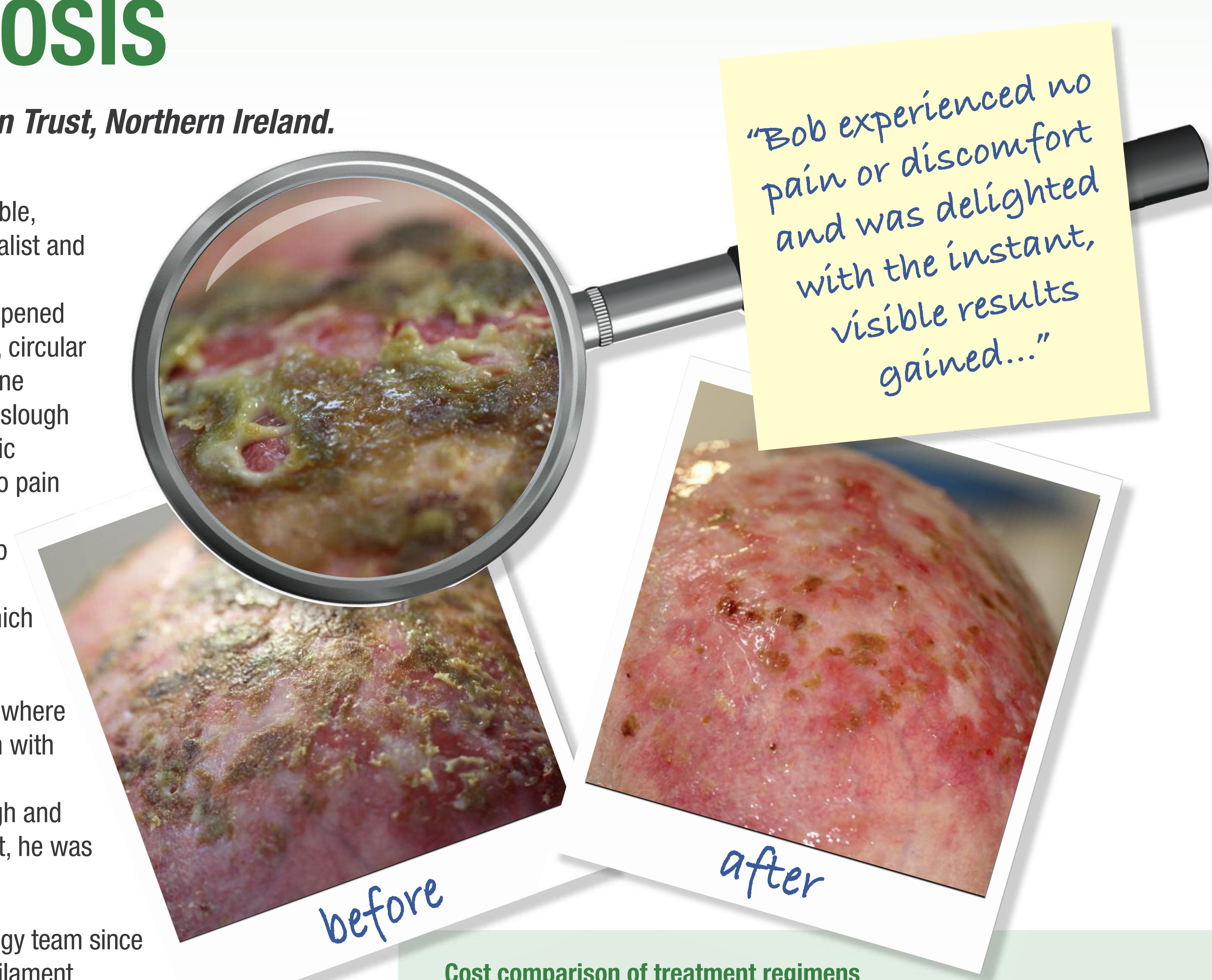
Bob attended clinic for one follow-up appointment, where the monofilament debridement pad was used again with good effect. It was evident that, unlike the previous treatment which allowed a further build-up of slough and scaling, this was no longer the case and, as a result, he was referred back to the care of his Practice Nurse.

Bob has not been back to see the hospital dermatology team since July 2014 and continues to self-care with the monofilament debridement pad. He is also reviewed by his Practice Nurse twice a month.

This case study has resulted in a change in service provision for patients suffering from the distressing, lifelong condition of AK.

This case study demonstrates;

- pain free, safe and effective treatment regime improving concordance and quality of life for Bob
- reduced treatment costs and specialist hospital intervention
- a promise for the use of the monofilament pad* in Dermatology



Cost comparison of treatment regimens

Regimen 1: December 2013 - March 2014

Dermatology OP - Multiple professionals, first appointment **£133**

Dermatology OP - Single professional, 50 x follow up appointments*, plus costs for Gauze and Saline **£3,382**

Total £3,515

Regimen 2: April 2014 - August 2014

Dermatology OP - Single professional, 4 x follow up appointments @ £68 each **£272**

14 x Practice Nurse appointments♦, plus costs for monofilament debridement pad* for clinic and self-care **£344**

Total £616

* PbR Tariff Rates ♦ PSSRU University of Kent Rates for Practice Nurse

References

† de Berker et al (2007) Guidelines for the management of actinic keratosis. British Journal of Dermatology 2007 156, pp222-230