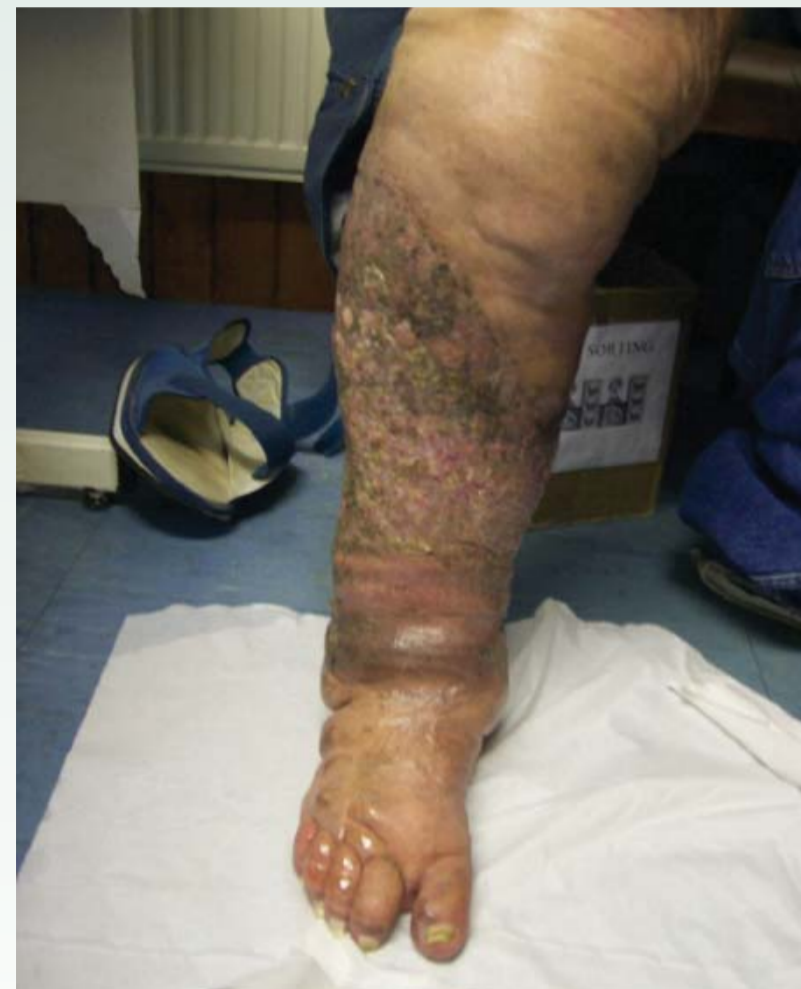


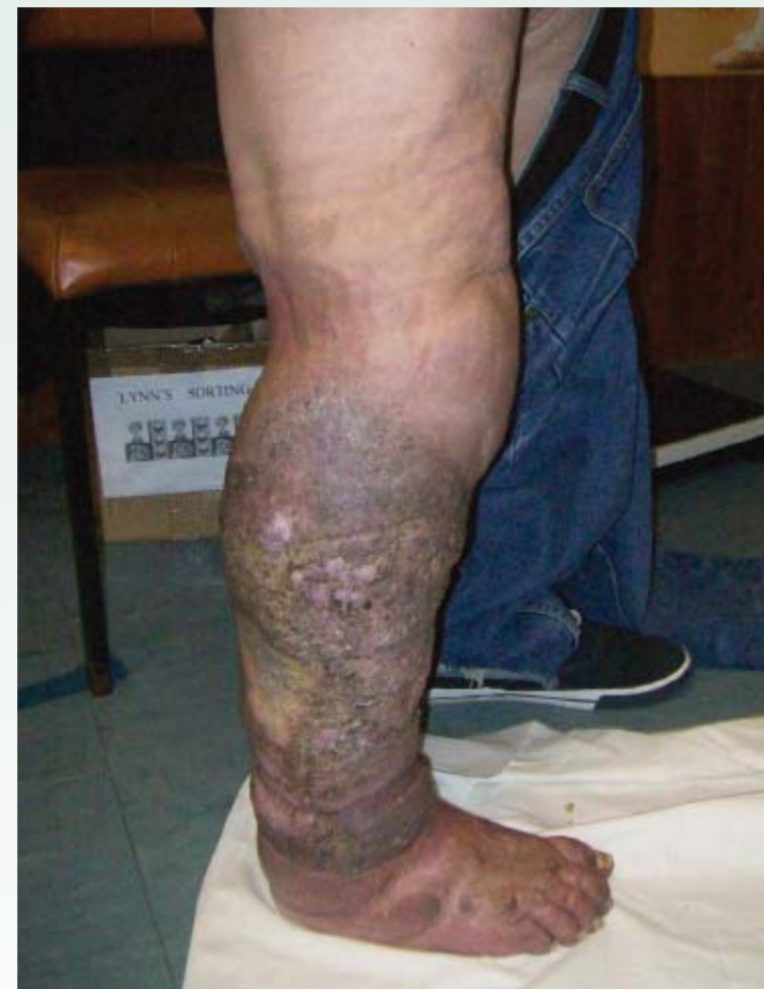# The management of a patient with bilateral lymphoedema and papillomatosis



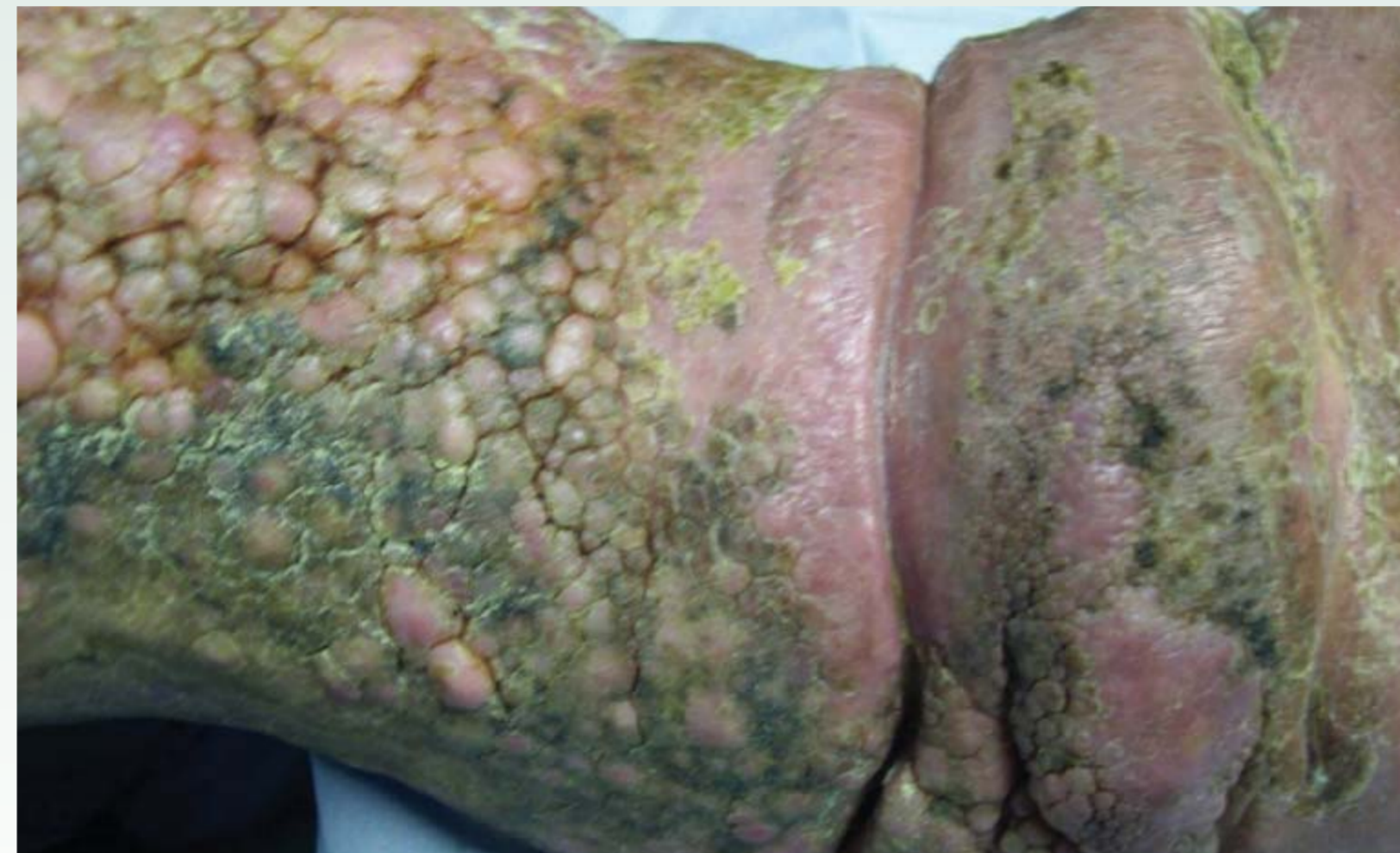Carole Harding, Practice Nurse, Thornhill Centre for Health, Southampton.



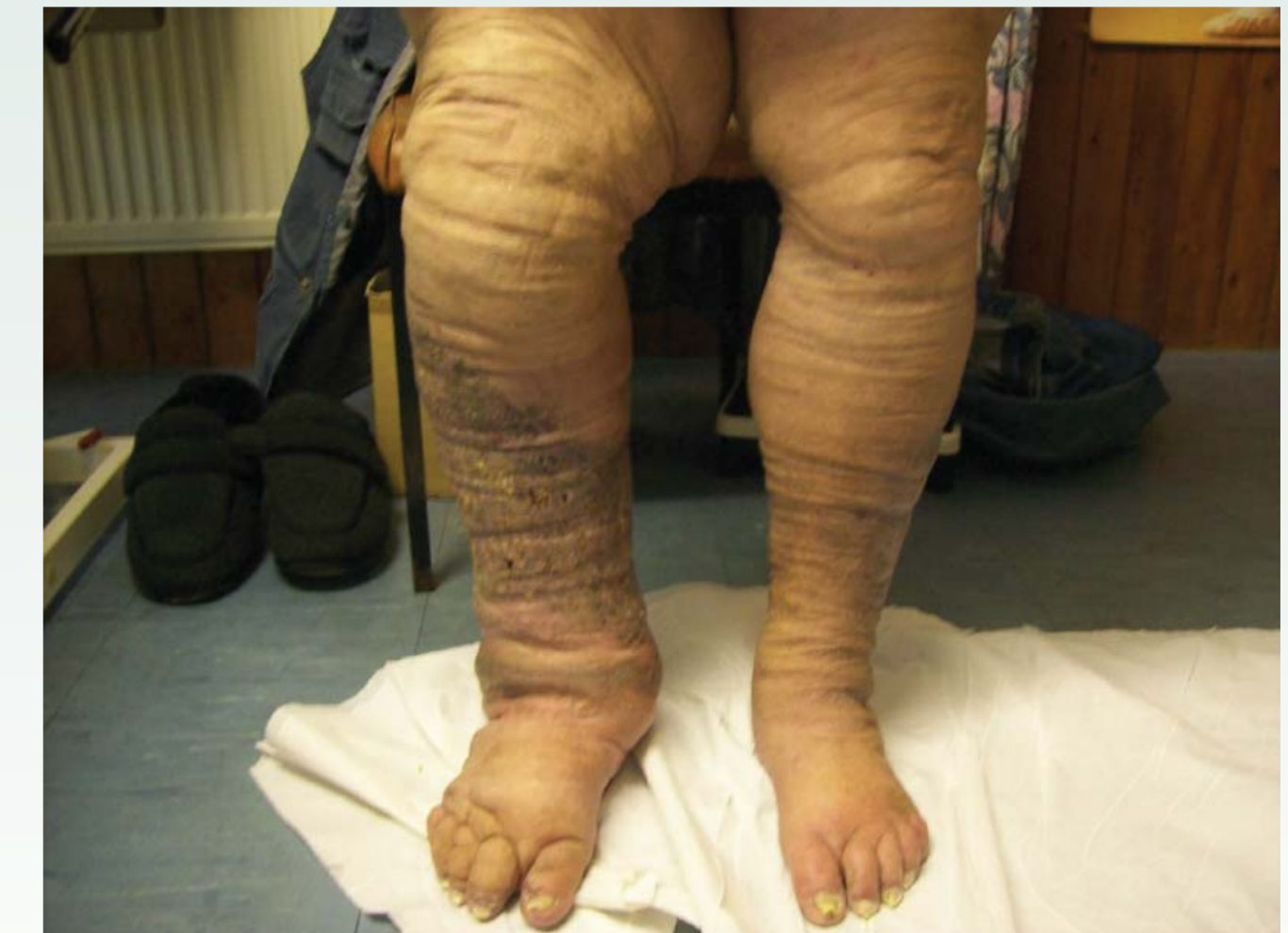Picture 1: March - April 2012



Picture 2: March - April 2012



Picture 3: March - April 2012



Picture 4: August 2012

## Background

Lymphoedema is a chronic and permanent swelling that can affect any area of the body, most commonly affecting the limbs. It is a long-term condition that cannot be cured, but it can be managed well with treatment. Lymphoedema has not always been considered a health priority in the UK and is often poorly managed, leading to considerable waste of resources and avoidable hospitalisation.

This case study demonstrates that a partnership with industry to deliver education, training and support can be beneficial to patient care without jeopardising integrity or independence as an NHS organisation.

Mr EM was a 69 year old gentleman who suffered from lymphoedema. He had become very depressed after bereavement and had stopped caring for himself. His quality of life was very poor.

He had been discharged home from hospital following a 2 month admission with chronic septicaemia resulting from an insect bite. He was discharged under the care of the Practice Nurse (Pictures 1 & 2).

As is often the case, no one in the practice was trained to deliver lymphoedema care, but with the support of the Tissue Viability Clinical Nurse Specialist and the Chronic Oedema Therapy Trainer industry representative the patient received the holistic care he required.

## Methods

Mr EM suffered from papillomatosis. This is a common skin change secondary to lymphoedema and presents as firm, raised projections of skin due to dilation of lymphatic vessels and fibrosis sometimes associated with hyperkeratosis (Picture 3).

The aims of Mr EM's management were based on the four main components;

- skin care and prevention measures – this was achieved by using a monofilament debridement pad\* to remove hyperkeratosis and reduce the papillomatosis. This also removed devitalised tissue colonised with *Pseudomonas aeruginosa* micro-organism which had caused malodour
- exercise, movement and positioning
- lymphatic drainage
- external compression and support – this was achieved by initially using a cohesive inelastic short stretch bandage\*\* as recommended in the lymphoedema framework document (Lymphoedema Framework, 2006). It is a stiffer bandage and is better at managing and preventing oedema. Mr EM progressed to Made to Measure hosiery\*\*\* to continue with the long term management

## Results

Over a 3 week period there was a dramatic reduction in limb circumference in the right and left limbs.

Right leg	Before treatment	After treatment
Ankle	39cm	29cm
Calf	49cm	49cm – no change
Thigh	72cm	61cm

Left leg	Before treatment	After treatment
Ankle	38cm	28cm
Calf	47cm	46cm
Thigh	69cm	60cm

## Conclusions

With correct management and a team effort Mr EM received effective, evidence based lymphoedema care close to home. The monofilament debridement pad contributed greatly to the skin care regime and effectively reduced the hyperkeratosis and papillomatosis (Picture 4). The overall effective management was responsible for improving his quality of life, enabling him to walk easily and socialise, reducing the effects of his depression.

## References

Lymphoedema Framework (2006) Best Practice for the Management of Lymphoedema. An International Consensus. MEP, London.