

# USING A LEG ULCER HOSIERY KIT TO MEET COMPLEX NEEDS IN A CHALLENGING ENVIRONMENT: DRIVING WOUND-CARE IMPROVEMENT IN HMP LEEDS



Sian Dillon BAND 6 PROJECT LEAD    Michelle Eaglen BAND 6 PROJECT LEAD

## About HMP Leeds...

- a category B remand prison
- houses 1200 male offenders over the age of 21
- has a diverse population
- offenders have varying complex health needs, including:
  - physical disabilities
  - learning difficulties
  - chronic conditions
  - drug and alcohol dependency
  - mental health issues

In 2013 a formal investigation led by a Community Nursing Service Manager highlighted a service improvement requirement with regards to wound care delivery within HMP Leeds.

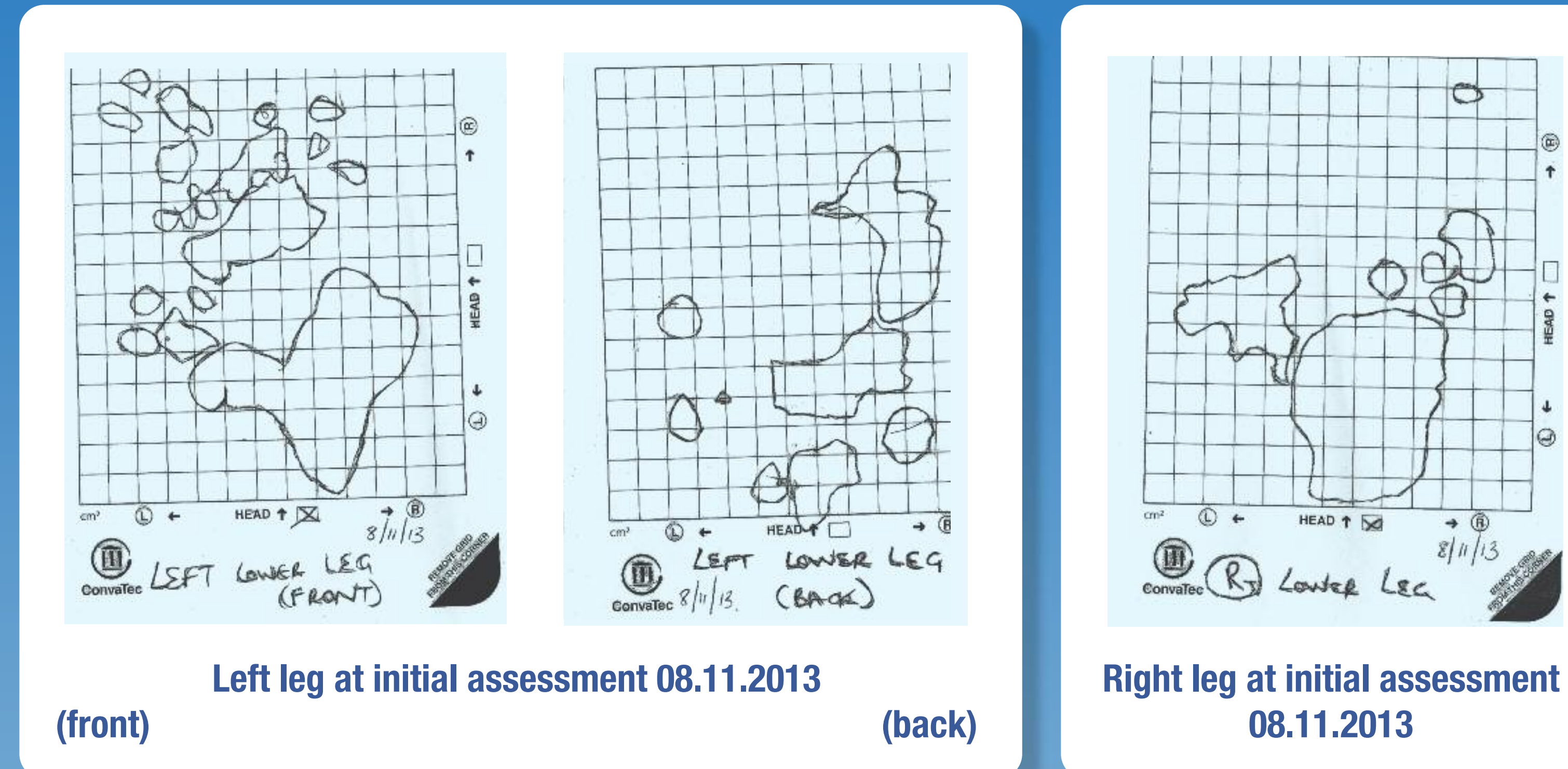
The VenUS IV Study (Ashby et al. 2014) highlighted some clinical and cost benefits of using hosiery to manage venous leg ulceration in comparison to 4-layer bandaging. These benefits are illustrated in Allun's story (not his real name).

Allun has a history of long-standing bilateral leg ulceration. He has Psoriatic Arthropathy and multiple joint pain, and is currently awaiting treatment for Hepatitis C, which he can receive once the ulcers heal.

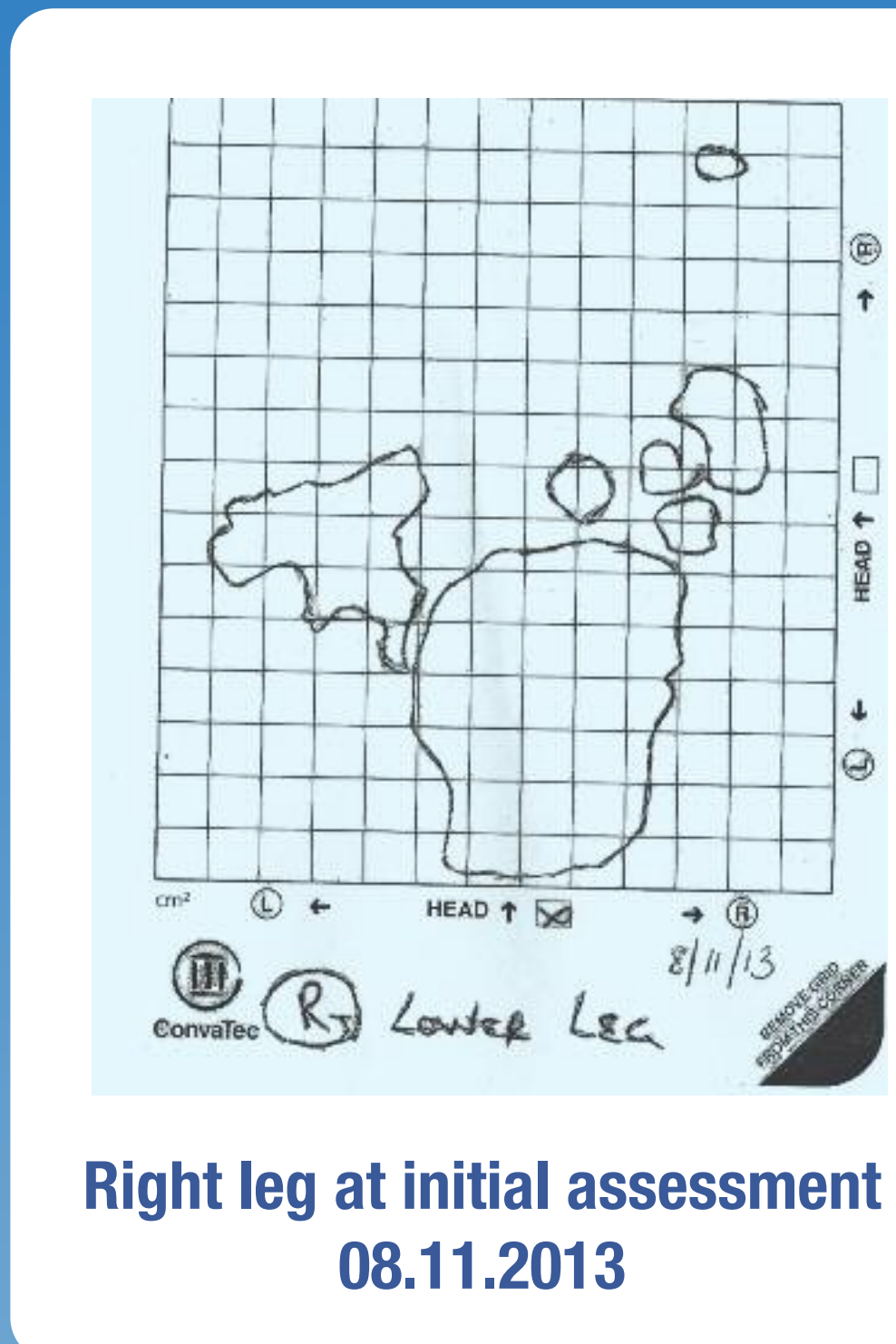
Initial assessment took place in November 2013. Both legs were reddened and covered with sloughy, infected ulcers. He informed us that his legs were always like this and never get any better, which upset him greatly as the condition of his legs was delaying his Hepatitis C treatment. He reported that the use of adhesive dressings and bandages had previously caused irritation.

A treatment plan including skin care, absorbent dressings and compression using leg ulcer hosiery kits\* to both legs. Various skin preparations were tested, but caused irritation. In April 2014, following TVN support, a topical steroid and antibiotic were introduced to the treatment regime.


*He informed us that his legs were always like this and never get any better, which upset him greatly as the condition of his legs was delaying his Hepatitis C treatment.*




Left leg at initial assessment 08.11.2013 (front) (back)



Right leg at initial assessment 08.11.2013




Left leg (front) 24.01.2014

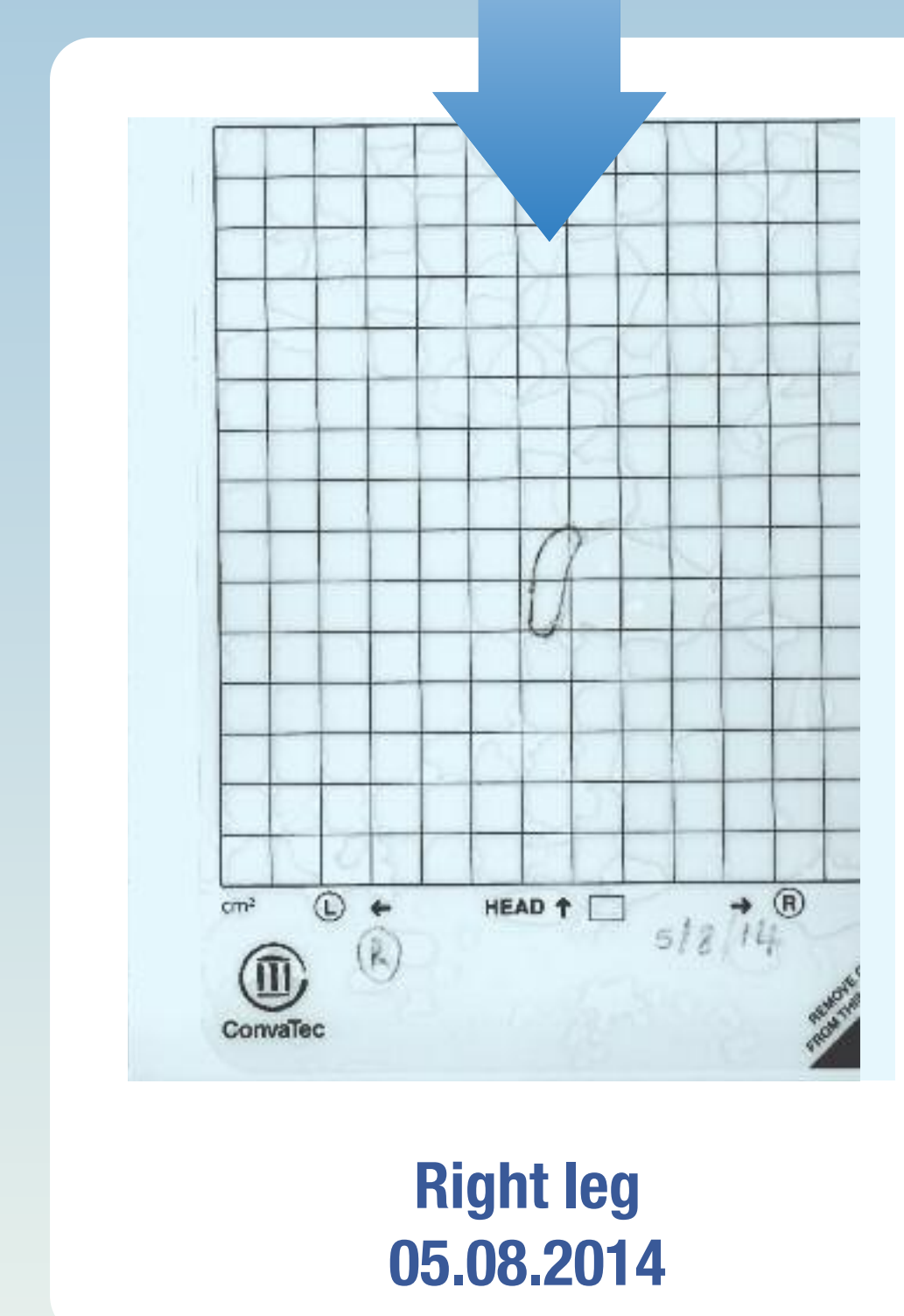

Right leg 24.01.2014

**A dramatic improvement was noted to both legs.**



Left leg (front) 05.08.2014



Right leg 05.08.2014

## Results

In 1 month a dramatic improvement was noted to both legs. The ulcers were much smaller, pink and granulating and the surrounding skin was healthy.

The treatment plan has continued for a further 3 months, Allun's skin has not deteriorated since and his ulcers are significantly smaller. The right leg ulcer has nearly healed and the left leg ulcer is pink, granulating and progressing well. Allun's psychological well-being has improved greatly and there is confidence that it won't be long before he can commence his Hepatitis C treatment.

*The use of compression therapy to heal ulceration is common-place and competently practiced in the community (Williams 2009). Such practice should be transferrable across the settings.*

## Conclusion

The case study is an example of how the improvement project outcomes have been met.

The use of leg ulcer hosiery kits\* contributed to:

- the management of Allun's leg ulceration and chronic skin condition
- a positive clinical outcome
- cost minimisation
- improved quality of life following years of suffering
- improvements in wound-care provision in this challenging care setting